

Mouth control of competition- and breeding horses 2014

Results from *Landsmót hestamanna (LM)* and *Íslandsmót í hestaíþróttum (ÍM)*

The veterinary control “Fit for competition” performed at the two major national horse events in Iceland have revealed bit-related lesions to be a general problem in competition and breeding horses. Lesions on the bars, considered to be of most concern for animal welfare, were strongly related to curb bits with a port.

Preventive measures were applied with emphasis on providing information to the riders and elimination of risk factors. New rules banning the use of curb bits with a port in competition were put in force by the Icelandic Equestrian Association in the spring of 2014. Comparable rules have not been put in force in breeding shows but oral inspections (although not veterinary controls) were implemented.

This report is based on 1255 records from the examination of 624 horses competing in 5-gaited tests, 4-gaited tests, *tölt* (LM & ÍM), young riders (LM), or presented at breeding show (LM) in 2014. The results in 2014 reveal decisive reduction of the frequency of bit-related lesions compared to 2012. This is demonstrated by an increased frequency of horses with no findings, both in breeding and competition (Tables 1-3). The reduction in the frequency of lesions in the corners of the mouth and the adjacent buccal mucosa, found in both competition and breeding horses, is most likely a result of the increased attention put on the equine oral health and the riders’ attempt to prevent lesions.

Severe lesions located in the bar region had almost disappeared in the competition horses. This change was clearly a result of the ban of the use of curb bits with a port as the same trend was not seen for horses presented for breeding show where those bits are still in use. Some thickening of the soft tissue in the bar region was, however, a common finding and regarded as mild. It was in some cases reflecting the past (scar tissue) but also indicating pressure on this area within the limits of severe tissue damage.

Lesions in the gingiva adjacent to the first cheek teeth (P2) in the lower jaw were recorded for first time. Although those were usually rather small, they tended to be sore and were in those cases classified as severe. The lesions were most likely due to pressure from the bit although they were in some cases found in horses with other problems (especially horses chewing on the bit).

A total of 38 breeding horses had severe lesions on the bars of the mandible, most often characterized by prominent thickening or inflammation connected to the underlying bone. Nine of them also had ulcer on the top of the lesion and were consequently withdrawn from further participation. Most of the horses with records of a severe lesion on the bars prior to the second presentation (61%) had been ridden with double jointed curb bit with a port in the first presentation. One horse had been ridden with an unjointed curb bit with a port. Ordinary Icelandic curb bits had been used in 26% of the horses, in some cases as findings at the first examination resulted in warnings against the use of bits with a port.

Severe lesions on the bars of the mandible were on the other hand only recorded in one competition horse.

The results demonstrate the positive effect of the preventive measures implemented. Education in the field of equine oral health helped in reducing the frequency of lesions in the corners of the mouth but the ban of the use of curb bits with a port was found to be necessary for reducing the frequency of severe lesions in the bar region.

Table 1. Records from examination of the rostral part of the mouth of competition horses and breeding horses prior to the preliminary rounds or first presentation at the two major national horse events in Iceland in 2012 and 2014

Preliminary rounds	N	No findings	Lesions in the corners of the mouth/ cheeks		Lesions on the bars	
			mild	severe	mild	severe
Competition 2012	350	189 54%	101 29%	18 5%	29 8%	13 4%
Breeding 2012	208	121 58%	49 24%	9 4%	21 10%	8 4%
Competition 2014	370	267 72%	56 15%	11 3%	28 8%	0
Breeding 2014	241	163 67%	36 15%	2 <1%	31 13%	8 3%

Table 2. Records from examination of the rostral part of the mouth of competition horses and breeding horses prior to the semi-finals or second presentation at the two major national horse events in Iceland in 2012 and 2014

Semi-finals/ second round	N	No findings	Lesions in the corners of the mouth/ cheeks		Lesions on the bars	
			mild	severe	mild	severe
Competitions 2012	91	35 38%	35 38%	7 8%	7 8%	7 8%
Competitions 2014	91	63 69%	11 12%	0	12 15%	1 1%
Breeding 2014	230	104 45%	49 21%	4 2%	48 21%	25 11%

Table 3. Records from examination of the rostral part of the mouth of competition horses and breeding horses prior to the finals or award presentation at the two major national horse events in Iceland in 2012 and 2014

Finals / awards	N	No findings	Lesions in the corners of the mouth/ cheeks		Lesions on the bars	
			mild	severe	mild	severe
Competitions 2012	77	31 40%	20 26%	2 3%	7 9%	17 22%
Competitions 2014	72	45 63%	12 17%	1 <1%	10 14%	0
Breeding 2014	80	45 56%	10 13%	4 5%	4 5%	16 20%

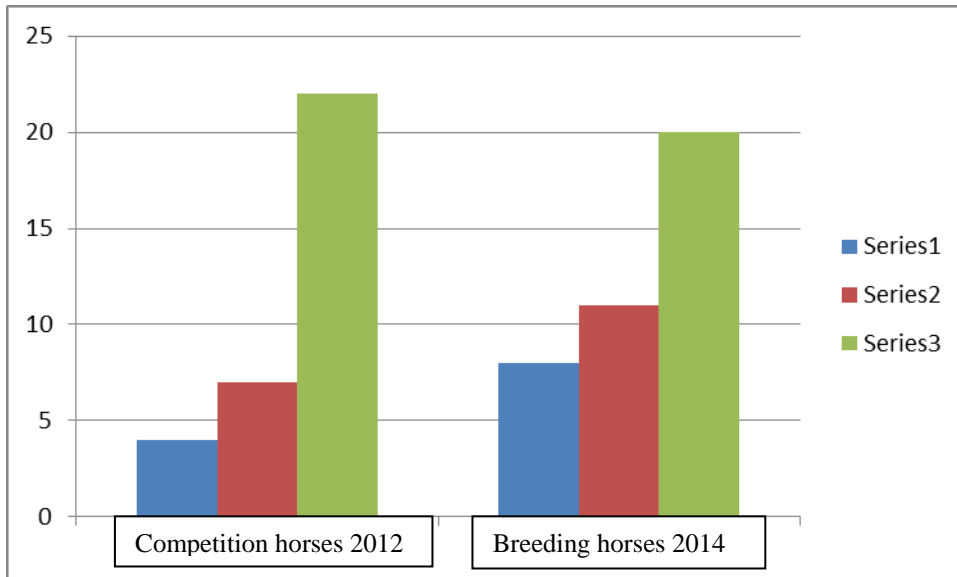


Figure 1.

Development in the frequency of severe lesions in the bar region in competition horses during LM 2012 and breeding horses during LM 2014

Blue bars: First examination (prior to preliminary rounds / first presentation)

Red bars: Second examination (prior to semi-finals / second presentation)

Green bars: Third examination (prior to finals / award presentation)

Hólar, 31.08.2014

Sigríður Björnsdóttir, DVM, PhD
 Veterinary Officer for Health and Welfare of the Horse,
 Icelandic Food and Veterinary Authority